

Case Study: Diabetic Foot Ulcer

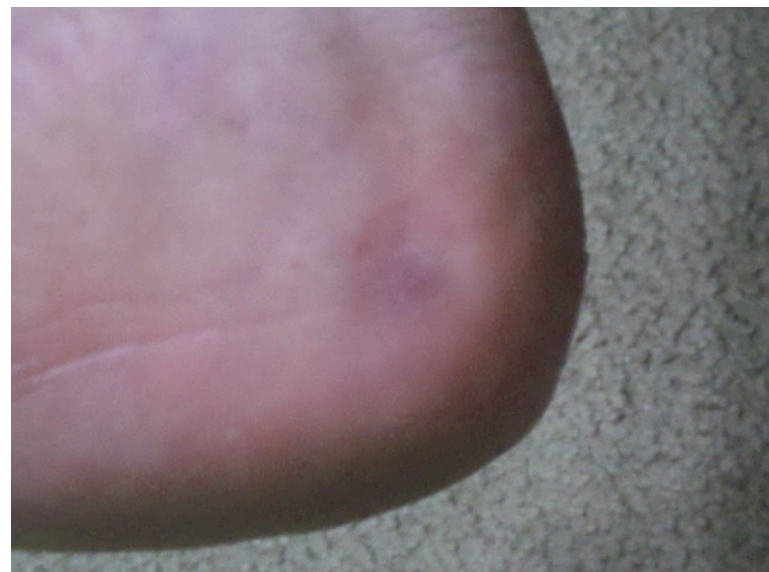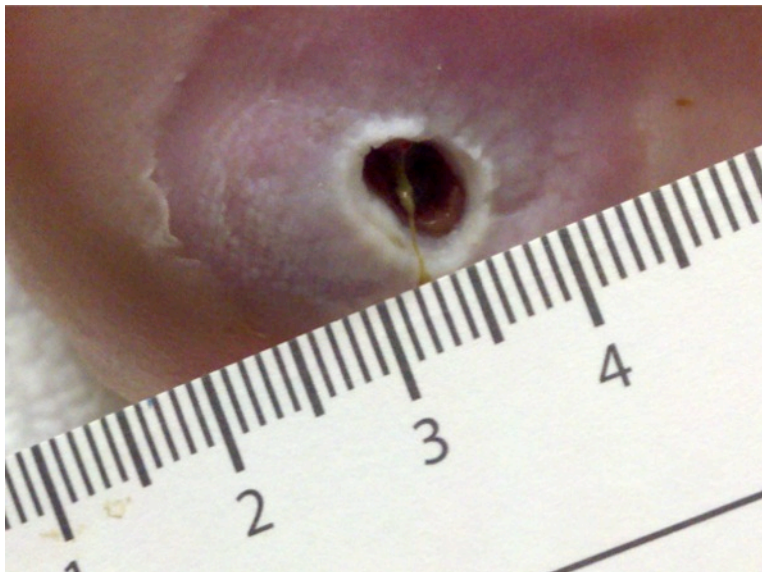


- 86 year old Caucasian male with a non-healing diabetic foot ulcer resulting from diabetes, open 120 days
- Comorbidities: diabetes, heart disease, marginal circulation, pain in legs & feet
- Previous therapies include: Medihoney™, MaxOrb® and Unna Boot (hyperbaric oxygen therapy recommended, yet not pursued due to distance for patient)
- Full closure achieved with CDO at 7 ml/hr by 61 days



Day 0 - Initiation of CDO

Followup - Day 135 (74 days after closure)



(110323HH - Pictures courtesy of Dr. Franklin Steele, MD, Valdese, North Carolina and Buffy Lamb, Resp-I-Care)